ARTICULATION DU POIGNET

Dr YEBDRI- CHABANE
LABORATOIRE D’ ANATOMIE
FACULTÉ DE MÉDECINE DE TIZI-OUZOU
site de Tamda

2019/2020

LE POIGNET

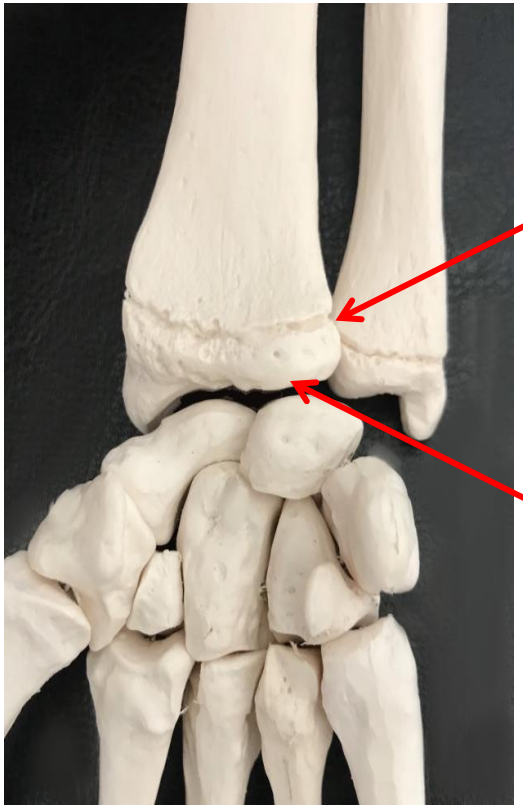

Articulation radio-Ulnaire distale

Diarthrose de type trochoïde.

Articulation Radio-carpienne

Diarthrose de type ellipsoïde.

COUPE **CORONALE**

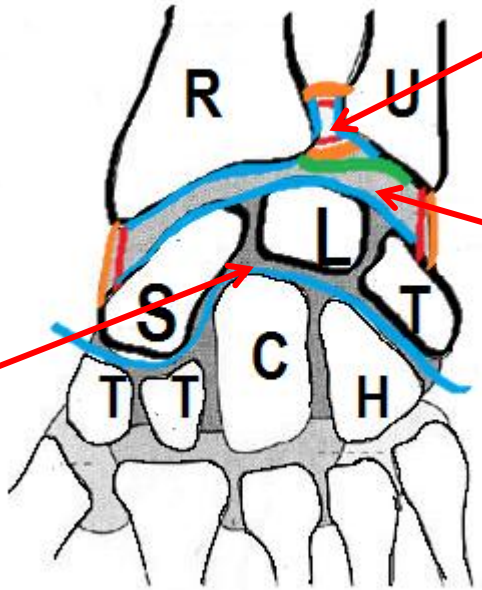

Articulation radio-Ulnaire distale

Articulation Radio-carpienne

Articulation médio-carpienne

ARTICULATION RADIO-ULNAIRE DISTALE

Vue ventrale

Prox.

Lat.

Incissure ulnaire

Bord circonférentiel
De la tête ulnaire

Ligaments radio-ulnaires ventral et dorsal

Vue ventrale

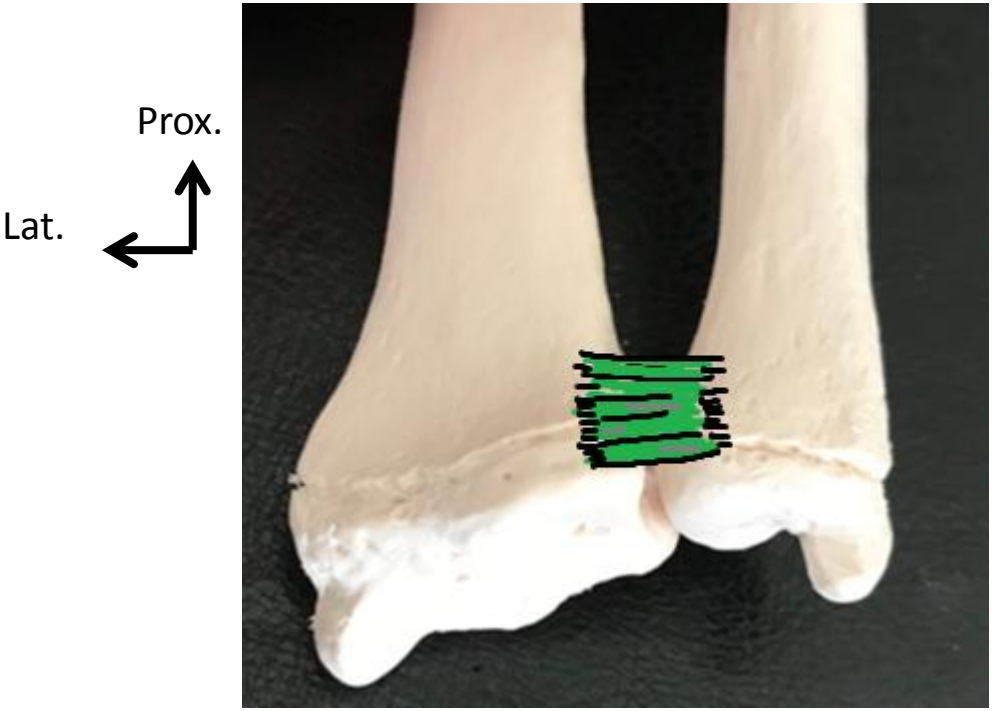

Vue dorsale

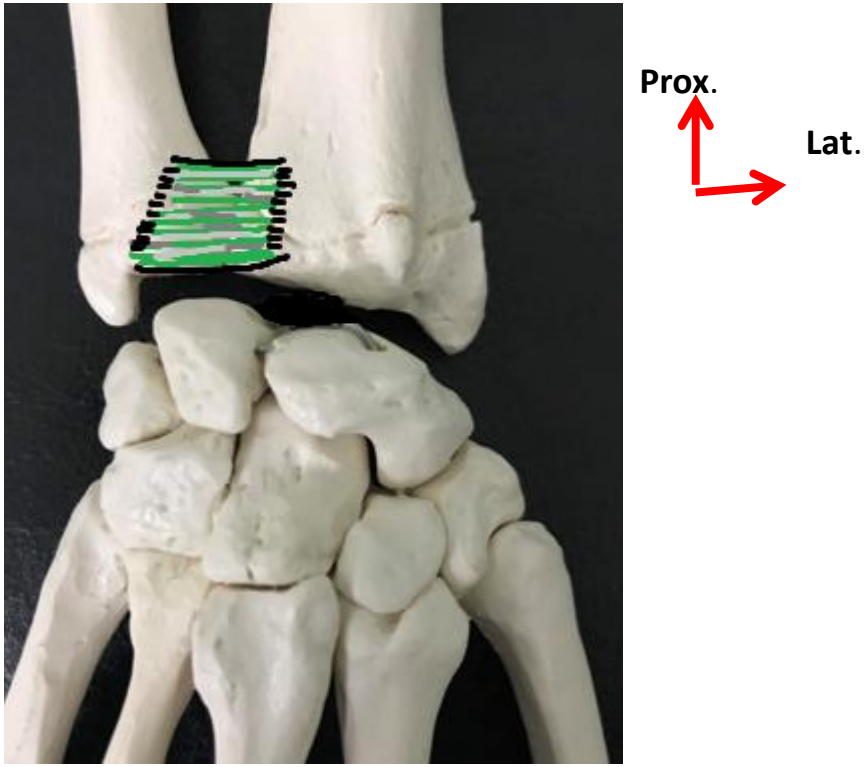

ARTICULATION RADIO-CARPIENNE

Diarthrose de type ellipsoïde.

Surfaces articulaires antébrachiales = glène antibrachiale

Face inférieure

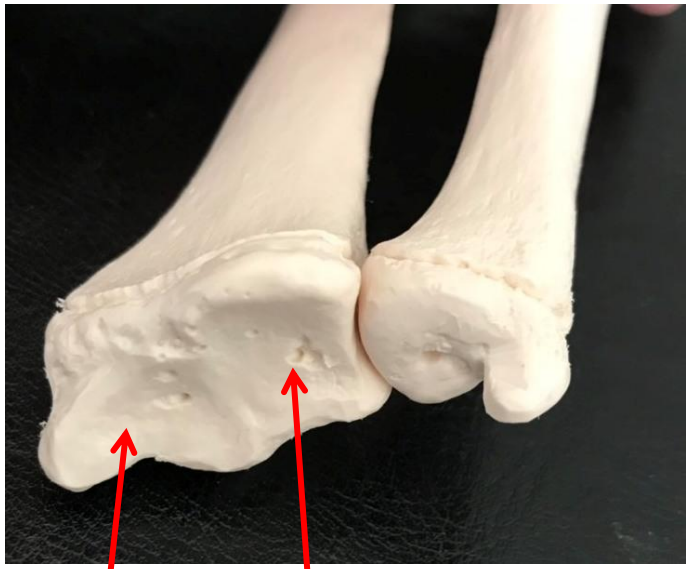

surface lunarienne

surface scaphoïdienne.

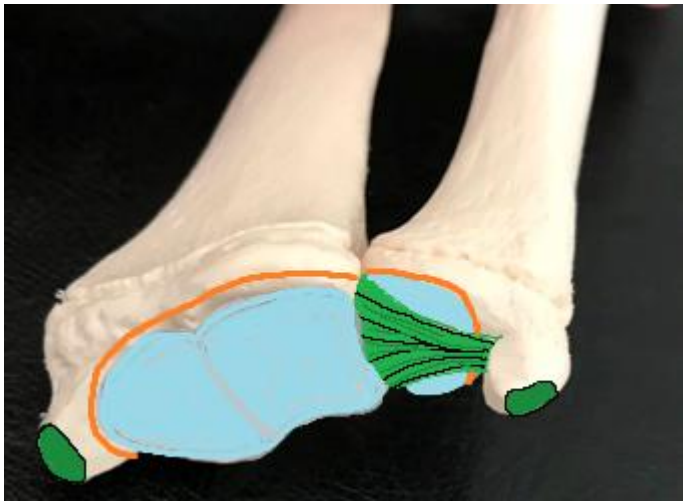

Surface arti.
Carpienne du radius

Disque articulaire

Surface radiale du carpe
= condyle carpien

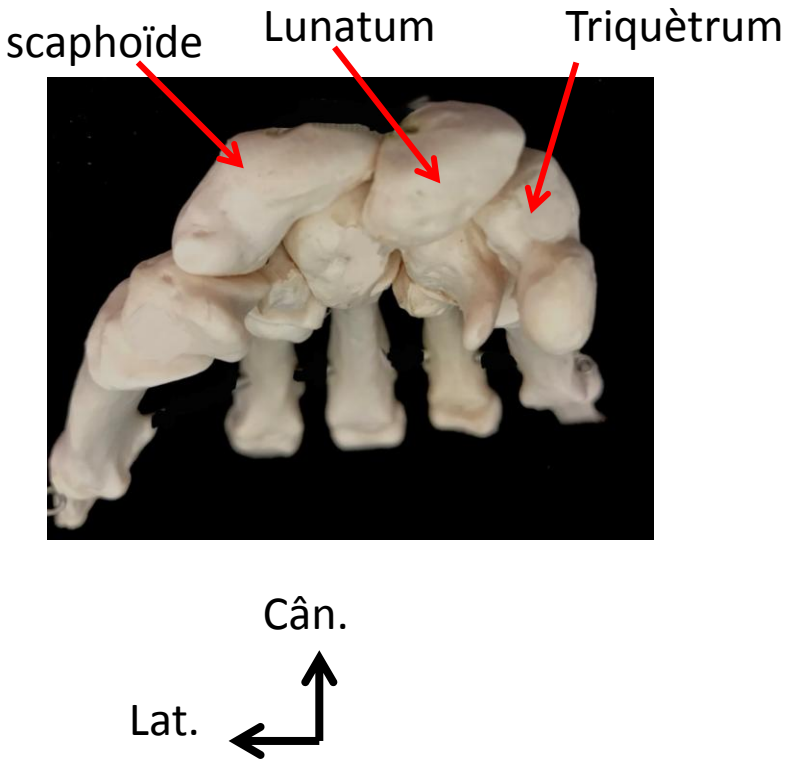

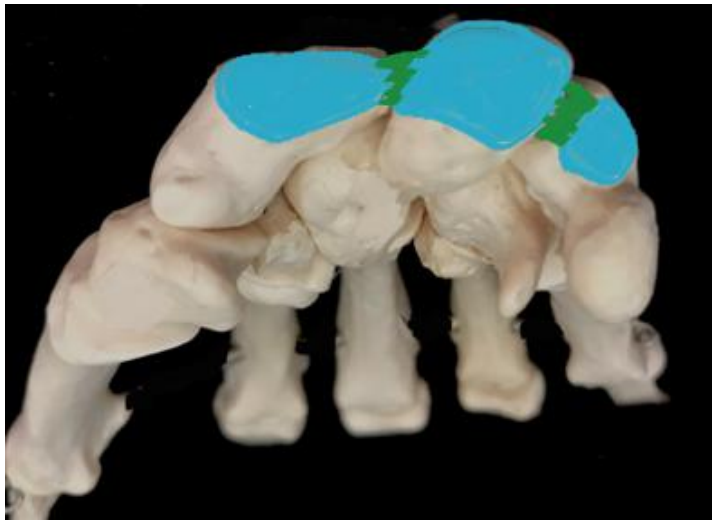

LIGAMENTS PALMAIRES

Vue ventrale

Prox.

Lat.

Lig. Radio-carpien palmaire

Lig. Collatéral Radial: fx ventral

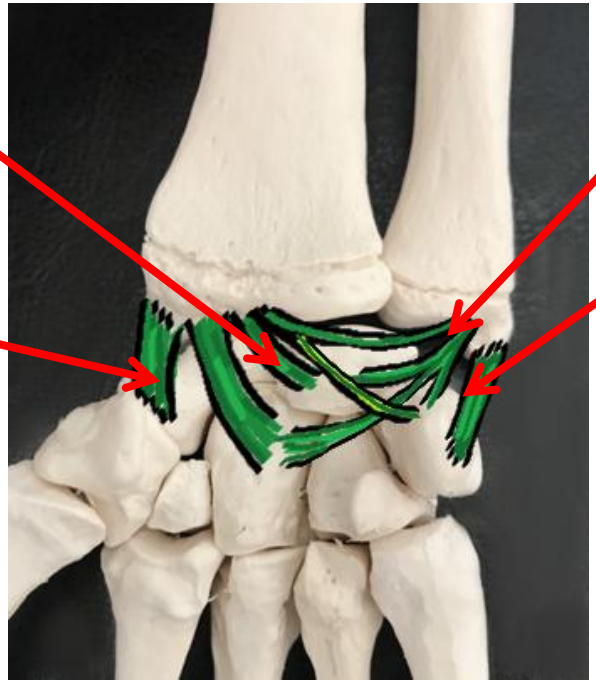

Lig. ulno-carpien palmaire

Lig. Collatéral Ulnaire : fx ventral

LIGAMENTS DORSAUX

Vue dorsale

Prox

.

Lat

.

Lig. ulno-carpien dorsal

Lig. Radio-carpien dorsal

Lig. Collatéral Ulnaire : fx dorsal

Lig. Collatéral radial : fx dorsal

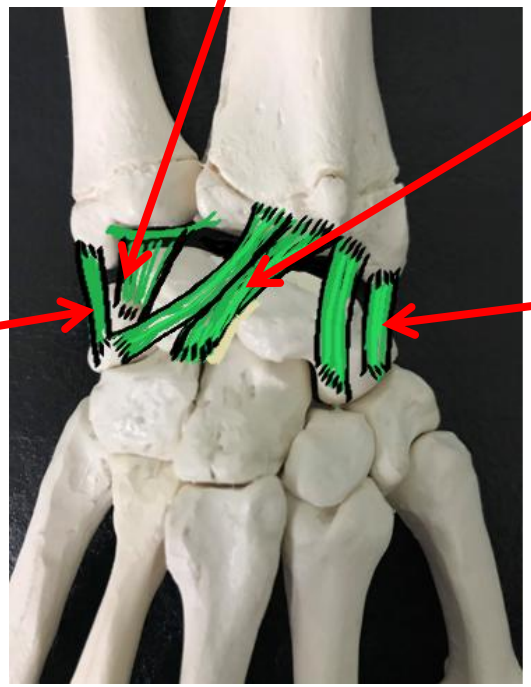

LIGAMENTS COLLATÉRAUX LATÉRAL ET MÉDIAL

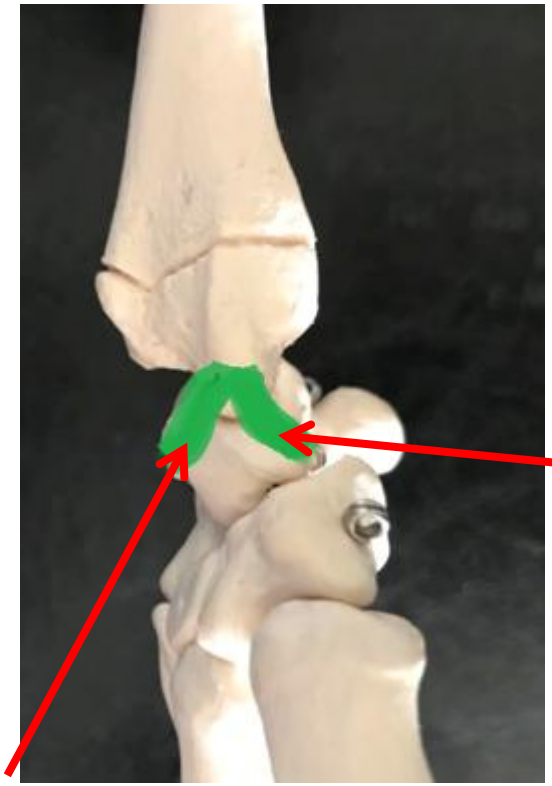

Lig. Collatéral Radial: fx ventral

Lig. Collatéral Radial: fx dorsal

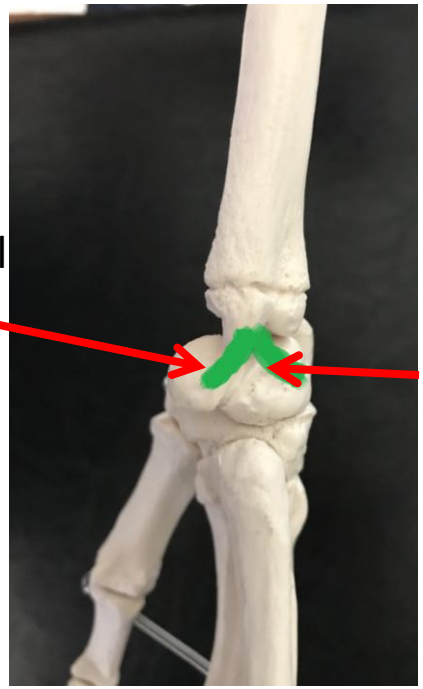

Lig. Collatéral ulnaire: fx ventral

Lig. Collatéral ulnaire: fx dorsal

Anatomie fonctionnelle.

Inclinaison ulnaire: 30° à 40°

Inclinaison radiale : 15° à 20°.

Flexion: 80° à 85°

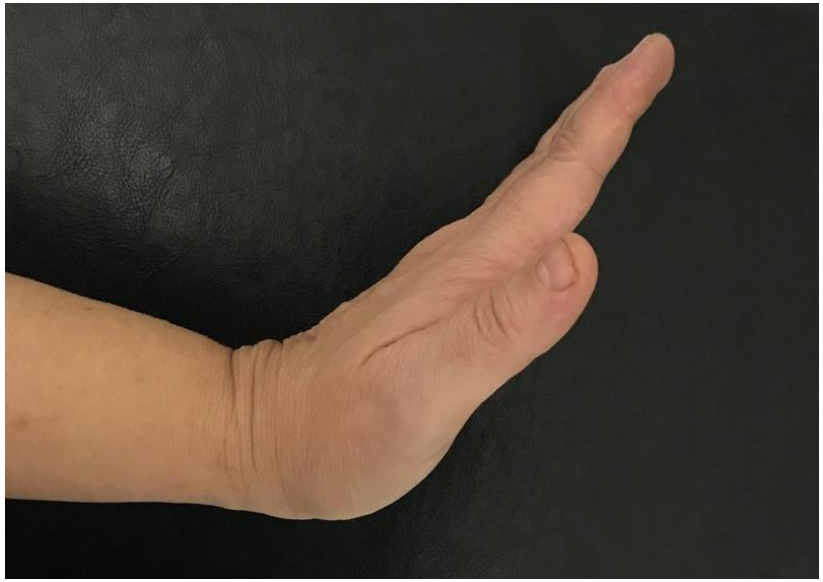

Extension: 80° à 85°

Repères anatomiques

- Ligne bi styloïdienne: oblique, la styloïde radiale descend plus bas que la styloïde ulnaire.
- L’index radio- ulnaire = 2mm
- Axe du radius est dans l’axe de M3.

- La tabatière anatomique.

Radiographie du poignet

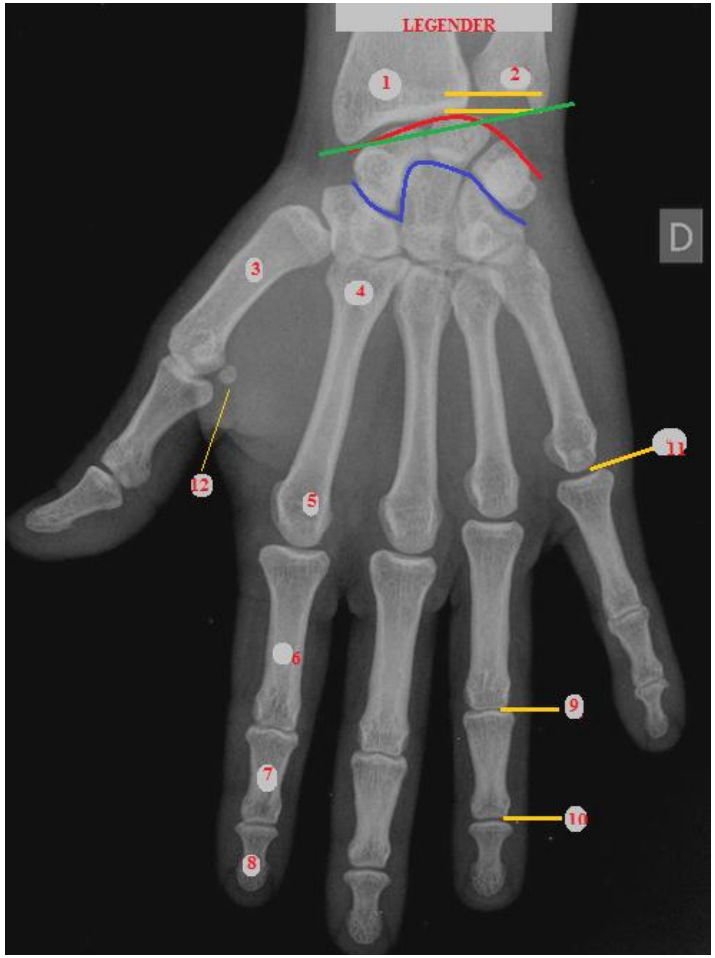

La tabatière anatomique

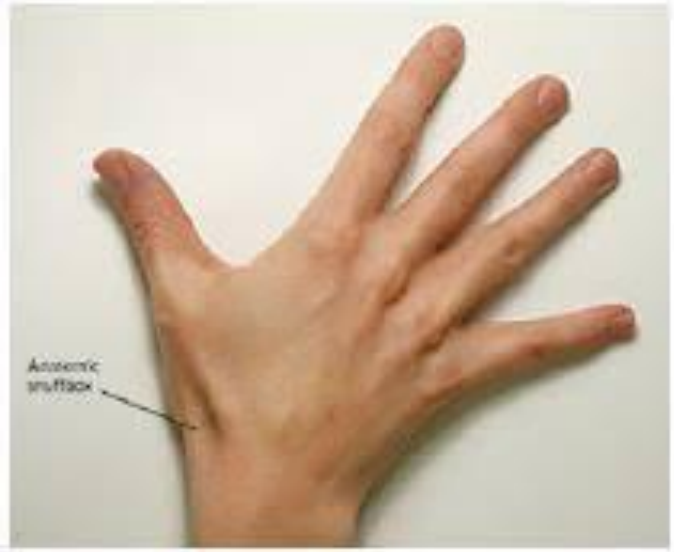

MERCI